



Contemporary practice of testicular prosthesis insertion

Aza Mohammed, Musaab Yassin, David Hendry & Gregory Walker

To cite this article: Aza Mohammed, Musaab Yassin, David Hendry & Gregory Walker (2015) Contemporary practice of testicular prosthesis insertion, Arab Journal of Urology, 13:4, 282-286, DOI: [10.1016/j.aju.2015.09.001](https://doi.org/10.1016/j.aju.2015.09.001)

To link to this article: <https://doi.org/10.1016/j.aju.2015.09.001>



© Arab Association of Urology



Published online: 05 Apr 2019.



Submit your article to this journal [↗](#)



Article views: 436



View related articles [↗](#)




View Crossmark data [↗](#)



Arab Journal of Urology
(Official Journal of the Arab Association of Urology)

www.sciencedirect.com



ANDROLOGY/SEXUAL MEDICINE
ORIGINAL ARTICLE

Contemporary practice of testicular prosthesis insertion



Aza Mohammed^{a,*}, Musaab Yassin^b, David Hendry^b, Gregory Walker^c

^a The Royal Derby Hospital, Derby, UK

^b Gartnavel General Hospital, Glasgow, UK

^c The Royal Hospital for Sick Children, Glasgow, UK

Received 4 July 2015, Received in revised form 22 August 2015, Accepted 2 September 2015

Available online 13 October 2015

KEYWORDS

Testicular cancer;
Undescended testes;
Orchidectomy;
Testicular prosthesis

ABBREVIATIONS

OR, odds ratio;
SMR, Scottish Morbidity Records;
TPI, testicular prosthesis insertion

Abstract Objectives: To assess the practice of testicular prosthesis insertion (TPI) related to orchidectomy in one geographical region and to identify the difference in the rates of insertion among different age groups.

Patients and methods: Males who underwent orchidectomy between 1989 and 2009 were identified from data collected from Scottish Morbidity Records. Patients were classified into six age groups. The TPI rate and relation to original orchidectomy were analysed according to different age groups.

Results: In all, 3364 patients underwent orchidectomy in the 20-year period of the study. The most common indications for orchidectomy were atrophy, undescended testes, torsion, and tumour. In the same period, 530 patients had a TPI, with 59.4% of them (316 patients) having TPI at initial surgery, 17.3% (92) as a second surgical procedure, and 22.8% (122) having the TPI without prior history of orchidectomy. Among patients who underwent TPI, postpubertal males were more likely to have simultaneous insertion at the time of orchidectomy than prepubertal males (83% vs 32%; odds ratio 10.44, 95% confidence interval 5.23–20.82; $P < 0.01$).

Conclusion: Younger males are more likely to have TPI at a later date. Paediatric urologists should be mindful of the possibility of concurrent TPI at the time of initial scrotal/groin exploration.

© 2015 Arab Association of Urology. Production and hosting by Elsevier B.V. This is an open access article under the CC BY-NC-ND license (<http://creativecommons.org/licenses/by-nc-nd/4.0/>).

* Corresponding author.

E-mail address: aza.mohammed16@gmail.com (A. Mohammed).

Peer review under responsibility of Arab Association of Urology.

Introduction

The presence of normal testes bilaterally plays an important role in the normal psychological development of young males and absence of a testis can have potential



Production and hosting by Elsevier

<http://dx.doi.org/10.1016/j.aju.2015.09.001>

2090-598X © 2015 Arab Association of Urology. Production and hosting by Elsevier B.V.

This is an open access article under the CC BY-NC-ND license (<http://creativecommons.org/licenses/by-nc-nd/4.0/>).

consequences as a result of loss of body image or masculinity [1,2]. Absence of an intrascrotal testis can be found in male patients at different ages, and this can be caused by agenesis, failure of normal testicular descent, or surgical removal. Orchidectomy is a common urological procedure and indications vary from benign conditions such as trauma or infection to testicular cancers.

In patients with absent testis, testicular prosthesis insertion (TPI) may be offered for cosmetic or psychological purposes. In appropriately sized patients, TPI can be done at the time of orchidectomy or as a subsequent elective procedure. Most patients report high levels of satisfaction after TPI [3,4]. In younger prepubertal boys, TPI at the time of surgery may not be appropriate due to difficulty in choosing the appropriate size of prosthesis and issues of informed consent.

In the present study, we aimed to identify the past and current indications for orchidectomy and the practice of TPI in one geographical region of the UK represented by the West of Scotland.

Patients and methods

This is a population-based retrospective study using a cohort of male patients who underwent orchidectomy in the City of Glasgow, Scotland over a 20-year period (1989–2009). This cohort was identified from the Scottish Morbidity Records (SMR) [5]. The SMR capture all episodes relating to inpatients and day-case patients discharged from non-psychiatric and non-obstetric wards in Scottish hospitals. Patients are provided with a unique identifying number that is used for clinical and research purposes.

From this cohort we identified males who underwent TPI using the SMR over the specified period using the unique identifying number. Data on the indications for orchidectomy and TPI were extracted from case notes review. This study has received approval from the Research Ethics Board and was conducted with accordance to the regulations of our local Audit Department.

The main outcomes for this study were the indications for orchidectomy in different age groups and the uptake of TPI in each of these groups.

Statistical analysis was performed using Statistical Package for the Social Sciences software SPSS Inc. (2007) Version 16.0. Chicago. We used the chi-squared test for the groups to determine the odds ratios (ORs).

Results

In all, 3364 patients were identified who had orchidectomy over the 20-year period. Those patients were subsequently divided into six age groups for statistical analysis as follows: 1, <13; 2, 13–15; 3, 16–20; 4, 21–30; 5, 31–40; and 6, >40 years.

This age thresholds have been used to distinguish between the paediatric age group, adolescents, and young adults. The distribution of orchidectomy across different age groups is shown in Table 1. The most frequent indications for orchidectomy are summarised in Table 2. The most common indications in pre- and peripubertal boys were atrophy, undescended testis and torsion, with malignancy becoming more common after the age of 16 years. Bilateral orchidectomy for hormonal manipulation in prostatic cancer was exclusive to the older age groups.

From this cohort we identified 530 patients who underwent TPI. The procedure was performed concurrently with orchidectomy in 316 patients (59.4%), while 92 (17.3%) had TPI performed at a later stage. In 122 patients (22.8%), TPI was undertaken without a previous record of orchidectomy. The rate of TPI and the timing related to orchidectomy were determined and are shown in Fig. 1.

Universally, the uptake of TPI was low and was performed (immediately or at a later stage) in only 15.76% of those patients undergoing orchidectomy. TPI particularly at the time of orchidectomy was more common in the older age groups (except the advanced age group). For patients who had TPI, those aged >16 years were more likely to have TPI at the same time as the original orchidectomy [302/364 (83%)] than patients aged <16 years [14/44 (32%)], OR 10.44 (95% CI 5.23–20.82; $P < 0.01$).

Discussion

The present study represents one of the largest orchidectomy and TPI cohorts in the literature. We considered all males undergoing orchidectomy in a single geographical region over a 20-year period and found a universally low rate of TPI, which is more marked in children and adolescents. Several surveys have considered the impact of loss of testis on the psychological wellbeing of affected males. Skoogh et al. [6] from the Swedish-Norwegian Testicular Cancer Group reported a significant proportion of men that underwent orchidectomy for non-seminomatous germ cell testicular cancer had feelings of loss and long-lasting shame, as well as loss

Table 1 The practice of orchidectomy across all age groups.

Age group, years	N (%)
<13	289 (8.6)
13–15	108 (3.2)
16–20	210 (6.2)
21–30	569 (16.9)
31–40	555 (16.5)
>40	1,633 (48.5)
All patients	3364 (100)

Table 2 Age distribution of the common indications for orchidectomy.

Indication for orchidectomy, %	Age group, years					
	<13	13–15	16–20	21–30	31–40	>40
Testicular atrophy	29.4	3.7	5.7	4.2	5.8	3.5
Undescended testis	20.8	28.7	31.0	23.9	16.4	6.4
Torsion	19.4	51.9	19.5	6.3	2.0	0.9
Testicular tumour	4.8	3.7	24.3	47.0	50.4	18.0
Inflammation	0.3	1.9	2.9	3.9	3.8	9.7
Vascular complications ^a	2.0	0.9	1.0	2.7	3.6	21.7
Hormonal manipulation for prostate cancer	0	0	0	0	0.2	21.0
Others	2.0	7.4	3.3	8.4	10.1	14.3
Indication unknown	21.3	1.8	12.3	3.6	6.7	4.5

^a Vascular impairment of the testis during inguinoscrotal surgery resulting in damage and subsequent orchidectomy.

of sexual desire as a result of orchidectomy. Testicular prosthesis or implants were introduced to give a sense of fullness in the scrotum and avoid psychological trauma. Modern day testicular prostheses are available in different sizes and made of silicone filled with gel or saline [7,8]. High satisfaction rates of patients after TPI are well documented and counselling patients for about TPI is an essential part in consenting patients undergoing orchidectomy [9–11].

The indications for orchidectomy in our present cohort were consistent with other reports [12,13]. While testicular atrophy was the leading indication for orchidectomy in the age groups <15 years, undescended testes is still a significant indication for orchidectomy, particularly in those aged 16–20 years. This may be explained by the fact that missed undescended testis usually presents at a later stage and surgery is usually advised due to the high risk of testicular cancer. Zaidi et al. [14] reached similar conclusions in their systematic review of orchidectomy and TPI in the paediatric population. In the older groups, orchidectomy for tumours accounts for a substantial proportion of procedures, with the highest incidence in the 31–40 year age group. Bilateral orchidectomy for the management of metastatic prostate cancer was prevalent in those aged >40 years, although there has been a general decline in this procedure as a result of the introduction of medical castration [15]. However, recent guidelines are in favour of bilateral orchidectomy as a result of proven efficacy and better cost-effectiveness, especially when castrate levels of testosterone are urgently required [16].

During the present study period, only 530 patients underwent TPI. The highest rate of TPI was seen in the males aged 13–30 years, perhaps reflecting the consciousness about self-image that is most prominent in this age group. However there are a large number of males with prior orchidectomy who did not undergo TPI. Given the retrospective nature of the present study, it is not possible to determine if testicular prosthesis was offered by the treating physician and declined by the patients, or whether no offer was made. Moynihan [17] interviewed 102 patients with testicular prosthesis and found that only 28% were offered TPI as part of

their counselling for orchidectomy and only 18% of those agreed to have one. On reflection, patients not offered TPI did not report concerns about loss of body image. Men who are in stable relationships are less likely to request a prosthesis after orchidectomy for cancer, with >50% of married men reporting satisfaction with body image without a prosthesis [18]. Our present study also identified 122 men (23%) who had TPI with no previous history of orchidectomy. This may be due to inconsistencies in reporting, previous surgery being undertaken outside the region, previous testicular trauma without surgery, or testicular agenesis/atrophy. An improvement in surgical coding is required to ensure accurate data entry for future research purposes.

Our present findings further confirmed that a number of prepubertal males requested TPI at a later stage following their orchidectomy (30/397, 8%). This implies increased awareness of body image later during puberty and adulthood, but the uptake remains low. Our present data may underestimate the number of young boys undergoing TPI after orchidectomy in early childhood, as some of those patients may wish to have TPI at a later stage of life or when they are sexually active. Many of these boys will have been discharged from paediatric services and will require referral to adult urologists, and GPs should be aware of this option. The pathway by which men presented for TPI at a later date is not clear, but the anecdotal experience of the authors suggests that these boys/men often self-present for referral to specialist services. There may be a disinclination to self-present related to embarrassment or reluctance to undergo another general anaesthetic. TPI at the time of original orchidectomy may increase the rate of uptake.

There is a general belief that younger men should not be offered TPI at the time of surgery because of an underdeveloped scrotum [19]. Zilberman et al. [20] interviewed 19 young adults who had TPI at early childhood and demonstrated good satisfaction rates in 62% of them. They concluded that the procedure can safely be performed at a young age. The pathology leading to orchidectomy may well influence the concurrent TPI. Younger boys were more likely to undergo an orchidectomy due to torsion or other inflammatory conditions

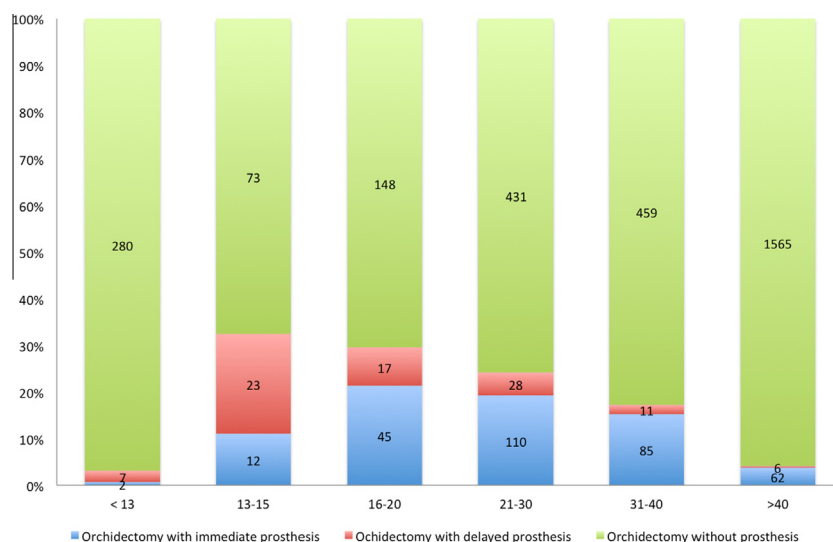


Figure 1 Timing of TPI after orchidectomy.

and it would be unadvisable to perform TPI in this setting. A robust follow-up service is required to ensure that patients and families are aware of the possibility of TPI to optimise uptake.

Limitations of the present study include the retrospective nature of data collection, which could affect the results, especially as there were no local guidelines at the time of writing of the manuscript that govern TPI. Another limitation of the present study is the lack of data on patients' satisfaction, the marital status of the patient, type of prosthesis, and complications after insertion.

Conclusions

The present study provides a 'snapshot' on the practice of TPI in the male population in the West of Scotland. It has shown inconsistencies in the rate of TPI, although it is not clear whether this is caused by failure of adequate counselling of patients or patient choice. Adequate mechanisms should be available for paediatric and pre-pubertal males after orchidectomy to offer TPI at a later stage. We hope that the present study will raise awareness and lead to robust systems in paediatric hospitals or GP surgeries to ensure adult patients with previous orchidectomy are counselled about TPI and to arrange referrals to adult urologists if necessary.

Conflicts of interest

None of the authors of this paper have any conflict of interests.

Source of funding

None.

Acknowledgement

The authors received no financial support for study design, data extraction, and dissemination of results through national and international conferences or writing the manuscript.

References

- [1] Friedman RM. The role of the testicles in male psychological development. *J Am Psychoanal Assoc* 1996;**44**:201–53.
- [2] Gurevich M, Bishop S, Bower J, Malka M, Nyhof-Young J. (Dis) embodying gender and sexuality in testicular cancer. *Soc Sci Med* 2004;**58**:1597–607.
- [3] Incrocci L, Bosch JL, Slob AK. Testicular prostheses: body image and sexual functioning. *BJU Int* 1999;**84**:1043–5.
- [4] Lynch MJ, Pryor JP. Testicular prostheses: the patient's perception. *Br J Urol* 1992;**70**:420–2.
- [5] Harley K, Jones C. Quality of Scottish Morbidity Record (SMR) data. *Health Bull (Edinb)* 1996;**54**:410–7.
- [6] Skoogh J, Steineck G, Cavallin-Stahl E, Wilderäng U, Håkansson B, Johansson B, et al. Feelings of loss and uneasiness or shame after removal of a testicle by orchidectomy: a population-based long-term follow-up of testicular cancer survivors. *Int J Androl* 2011;**34**:183–92.
- [7] Bodiwala D, Summerton DJ, Terry TR. Testicular prostheses: development and modern usage. *Ann R Coll Surg Engl* 2007;**89**:349–53.
- [8] Turek PJ, Master VA. Testicular Prosthesis Study G. Safety and effectiveness of a new saline filled testicular prosthesis. *J Urol* 2004;**172**:1427–30.
- [9] Money J, Solland R. Body image, plastic surgery (prosthetic testes) and Kallmann's syndrome. *Br J Med Psychol* 1978;**51**:91–4.
- [10] Robinson R, Tait C, Clarke N, Ramani V. Is it safe to insert a testicular prosthesis at the time of radical orchidectomy for testis cancer: an audit of 904 men undergoing radical orchidectomy. *BJU Int* 2014. <http://dx.doi.org/10.1111/bju.12920> [Epub ahead of print].
- [11] Xylinas E, Martinache G, Azancot V, Amsellem-Ouazana D, Saighi D, Flam T, et al. Testicular implants, patient's and partner's satisfaction: a questionnaire-based study of men after orchidectomy. *Prog Urol* 2008;**18**:1082–6.
- [12] Albers P, Albrecht W, Algaba F, Bokemeyer C, Cohn-Cedermark K, Fizazi K, et al. EAU guidelines on testicular cancer: 2011

- update. European Association of Urology. *Actas Urol Esp* 2012;**36**:127–45.
- [13] Mansbach JM, Forbes P, Peters C. Testicular torsion and risk factors for orchiectomy. *Arch Pediatr Adolesc Med* 2005;**159**:1167–71.
- [14] Zaidi T, Henderson L, Aziz A, Morabito A, Dickson A. Testicular Prosthesis, First Systematic Review In Paediatric Population. *J Pediatr Urol* 2009;**5**(Suppl. 1):S80.
- [15] Melton 3rd LJ, Alothman KI, Achenbach SJ, O'Fallon WM, Zinke H. Decline in bilateral orchiectomy for prostate cancer in Olmsted county, Minnesota, 1956–2000. *Mayo Clin Proc* 2001;**76**:1199–203.
- [16] Rohde V, Grabein K, Hessel F, Siebert U, Wasem J. Orchiectomy versus medical therapy with LH-RH analogues for the treatment of advanced prostatic carcinoma. *GMS Health Technol Assess* 2006;**2**:Doc13.
- [17] Moynihan C. Testicular cancer: the psychosocial problems of patients and their relatives. *Cancer Surv* 1987;**6**:477–510.
- [18] Gritz ER, Wellisch DK, Wang HJ, Siau J, Landsverk JA, Cosgrove MD. Long-term effects of testicular cancer on sexual functioning in married couples. *Cancer* 1989;**64**:1560–7.
- [19] Elder JS, Keating MA, Duckett JW. Infant testicular prostheses. *J Urol* 1989;**141**:1413–5.
- [20] Zilberman D, Winkler H, Kleinmann N, Raviv G, Chertin B, Ramon J, et al. Testicular prosthesis insertion following testicular loss or atrophy during early childhood – technical aspects and evaluation of patient satisfaction. *J Pediatr Urol* 2007;**3**:461–5.